Journal of Manipulative and Physiological Therapeutics
Volume 22 • Number 6 • July/August 1999
0161-4754/99/$8.00 + 0 **76/1/99794** © 1999 JMPT

CASE REPORTS

Chiropractic Treatment of Coccygodynia via Instrumental Adjusting Procedures Using Activator Methods Chiropractic Technique

Bradley S. Polkinghorn, DC,[a] and Christopher J. Colloca, DC[b]

ABSTRACT

Objective: To discuss a case of coccygodynia that responded favorably to conservative chiropractic adjusting procedures with the Activator Methods Chiropractic Technique (AMCT) and the Activator II Adjusting Instrument (AAI II).

Clinical Features: A 29-year-old woman had unremitting coccygeal pain of 3 weeks' duration. The problem began after she had moved heavy boxes while at work. The pain was characterized by a continual dull ache in the coccygeal region, accompanied by intermittent sharp pain, particularly upon sitting or rising from a seated position. She had been taking self-prescribed over-the-counter analgesics (aspirin and ibuprofen) for 3 weeks without obtaining relief.

Intervention and Outcome: Treatment consisted of mechanical force, manually assisted, short-lever (MFMA) chiropractic adjusting procedures to the coccygeal area, primarily the sacrococcygeal ligament. The AAI II was used to deliver the adjustment according to diagnostic and treatment protocol specified for AMCT. The patient experienced a complete resolution of her pain after the first treatment.

Conclusion: Chiropractic coccygeal manipulation may be effectively delivered via instrumental adjustment in certain cases of coccygodynia. The use of an AAI II in administering the coccygeal adjustment has the benefit of being a gentle, noninvasive procedure, as well as being comfortably tolerated by the patient. This method of coccygeal adjustment may bear consideration in certain cases of coccygodynia. (J Manipulative Physiol Ther 1999;22:411-6)

Key Indexing Terms: Chiropractic Manipulation; Coccyx; Pain

INTRODUCTION

Coccygodynia (also called coccydynia), a distressing condition characterized by pain in and near the coccyx, was first described by Simpson in 1861.[1] Discomfort is usually felt when sitting or when rising from the seated position. This may indicate coccygeal luxation or hypermobility likely corresponding to movement of the coccyx back to its resting, neutral position.[2] The pain of coccygodynia may range from mild to severe; and urogenital, rectal, and sciatic-like complaints and general nervousness may be associated.[3] It is more common in women than men.[4] A fall or similar trauma (as well as the birth process) may result in a sprain of the sacrococcygeal ligaments, with the resulting onset of symptoms. In the majority of cases, however, there is no specific identifiable cause, and the results of imaging studies are typically normal.[5] In the absence of well-defined pathologic conditions such as recent fracture, neoplasm, avascular necrosis, perineural cysts, or infectious diseases, a mechanical basis for the pain is most likely.

Different types of mechanical lesions may be involved in the production of coccygodynia. Like most examiners, Schafer[4] believes that frank misalignment of the coccyx itself represents the usual mechanical lesion. Maigne et al[6] reported that common coccygeal pain originates from instability of the coccygeal disk in up to 70% of cases, and more recently Maigne and Tamalet[2] noted that it occurs in 48.4% of patients with a luxation or hypermobility of the coccyx. Cox has proposed that coccygodynia may, in fact, be another manifestation of lumbar degenerative disc disease,[7] because it has been shown by Lora and Long[8] that stimulation of the L3-4, L4-5, and L5-S1 facets characteristically produces sensation or reproduces referred pain in the coccyx. Little research has investigated the exact mechanisms involved in coccygodynia, with most research on the area focusing on utilization of the coccygeal discs as controls for the biomechanical study of intervertebral disks.[9-11]

The treatment of coccygodynia varies and includes nonsteroidal anti-inflammatory drugs, use of doughnut cushion while sitting, local injection with corticosteroids, local anesthetic, manual manipulation, and even coccygectomy (in up to 20% of all cases).[5,12-14] A 1991 study by Wray[12] found physical therapy (comprised of ultrasound and diathermy) to be ineffective in treating coccygodynia, with better results noted by using corticosteroid injections and manipulation. Injections, however, are a delicate matter and can require fluoroscopic guidance for maximum effectiveness.[5]

[a]Private practice of chiropractic, Santa Monica, California.
[b]Postdoctoral and Related Professional Education Department Faculty, Logan College of Chiropractic; Private practice of chiropractic, Phoenix, Arizona; and Activator Methods, Inc, Phoenix, Arizona
Submit requests for reprints to: Bradley S. Polkinghorn, DC, 901 Montana Ave, Suite A-West, Santa Monica, CA 90403.
Paper submitted September 21, 1998; in revised form October 20, 1998.
This work was supported in part by The National Institute of Chiropractic Research.

Chiropractic physicians are often called upon to treat this painful disorder and usually rely upon manual manipulation as the therapeutic approach of preference. Because of its close anatomical association with the pelvis, conventional manual manipulation of the lumbosacral spine can help to provide relief from coccygodynia symptoms, particularly in those instances wherein the pain may be a referred manifestation of lumbosacral involvement.[7] In the presence of coccygeal subluxation, however, direct manipulation of the coccyx is often required to address the underlying condition.[12]

Methods of coccygeal manipulation vary. Most of them involve per rectal adjustment of the coccyx.[12,13,15,16] This approach often causes apprehension in the patient and is therefore avoided by many practitioners. The procedure is usually performed with the patient prone or in the left lateral decubitis position, with the index finger per rectum, with the thumb overlying the external coccyx. The coccyx is either gently pulled posterior or repeatedly flexed and extended over a period of approximately 1 minute.[12,15] The patient may find the procedure to be uncomfortable or unpleasant. Many doctors of chiropractic do not possess the equipment or facilities necessary to perform this type of internal rectal coccygeal manipulation. Extensive clinical training in this procedure and experience in the methodology are often lacking as well.

An alternative approach to internal coccygeal manipulation is available via external manipulation. By contacting the coccyx 2 to 3 cm inferior to the sacrococcygeal junction with the thumb externally, tissue slack is removed and a thrust is given in an inferior to superior direction.[17]

Adjustment of the subluxated coccyx in cases of coccygodynia can often be accomplished by an external contact, instrumental adjustment, as well. This case report details one such example of successful treatment of coccygodynia, by using mechanical force, manually assisted short-lever (MFMA) chiropractic adjusting procedures. The coccygeal adjustments were performed with an Activator II Adjusting Instrument (Activator Methods, Inc, Phoenix, Ariz) (AAI II), by using diagnostic and adjusting protocols as specified for Activator Methods Chiropractic Technique (AMCT).[18-20] The Activator Adjusting Instrument (AAI) has been described previously in the bioscientific literature.[21-25]

CASE REPORT

A 29-year-old woman was referred by her supervisor for chiropractic evaluation and treatment regarding coccygeal pain that had begun 3 weeks earlier after moving heavy boxes during the course of her employment. The patient, normally employed as an administrator and unaccustomed to heavy lifting, stated that several days after that physical work she had a dull ache in her "tailbone," punctuated by episodes of intermittent sharp pain. The pain was aggravated while sitting and was particularly pronounced while rising from the seated position. She had taken different over-the-counter analgesics, including aspirin and ibuprofen, on a continuing basis without relief. She noted that the condition had been gradually worsening since its onset and she had been unable to work for the previous 2 weeks because of the severity of the pain. She rated her pain as 7 to 8 on a scale of 1 to 10. She reported having no previous history of the same or similar complaint in the past.

There was, on examination, tenderness and soft tissue swelling over the right lateral aspect of the apex of her coccyx. Pain was reproduced by having her sit on a hard surface and rise from a seated position. Lumbosacral range of motion was normal. Radiologic examination revealed a left lateral deviation of the coccyx on the anteroposterior view. The lateral view was unremarkable. Radiologic appearance of the coccyx can be helpful in arriving at a working diagnosis, but can also be deceptive. Congenital lateral deviation of the coccyx from the midline can be mistaken for a dislocation by those physicians who use roentgenography exclusively to confirm their diagnosis.[4] In a recent study assessing 10 patients with coccygeal luxation, radiographic follow-up demonstrated no change in coccyx alignment despite resolution of their symptoms at 2 months.[2] Clinical correlation between the radiologic findings and those of the physical and chiropractic examination must be made to determine the most appropriate treatment protocol.

Tests developed by Fuhr and others[18-20] for locating evidence of neurologic facilitation/subluxation revealed a right pelvic deficiency (PD) of ¾ inch with associated bilateral lumbopelvic subluxations. Adjustment of subluxation was made via an AAI. AMCT protocol was used for adjustment of the lumbopelvic biomechanics.[20,26] After the treatment of the lumbopelvic areas, the patient's leg lengths appeared even on visual examination. Similar responses have previously been reported in literature.[27] Utilizing isolation testing procedures associated with ACMT protocol,[20] evaluation for coccygeal subluxation/facilitation was made by instructing the patient to squeeze the gluteal muscles together, followed by relaxing. After compliance by the patient, the right leg (PD side) appeared upon visual examination to be approximately one half inch shorter than the left. This finding has been reported to be suggestive of coccygeal subluxation/facilitation.[20] Other isolation tests used in AMCT have been previously described and investigated in the scientific literature.[20,26,28-36] The legs were then gently flexed to 90 degrees, at which point the right leg (PD side) appeared approximately 1 inch longer than the left. This finding is said to indicate that the apex of the coccyx has subluxated laterally, contralateral to (ie, away from) the PD (short leg) side,[20] with the leg length discrepancy indicative of associated muscular hypertonicity. (Note: in this particular instance, the physical/chiropractic examination findings were consistent with those exhibited on the anteroposterior radiograph; however, this is not always the case.)

Contact was made by the AAI in the soft tissue at a point approximately one half inch lateral to the base of the coccyx on the side *opposite* the *apex* subluxation (right side, in this instance). The line of drive of the thrust was vectored in a superior and lateral direction. Following the adjustment, leg lengths appeared even and remained so, even after the administration of a "re-isolation" test wherein the patient

was instructed to again tighten the gluteal muscles as part of the post-adjustment evaluation procedure. Further adjustment was determined unwarranted, and treatment was therefore terminated. The patient reported that she felt some improvement in her pain immediately upon arising from the treatment table. No further treatment was given during that office visit. The use of a doughnut cushion was not recommended to her. No other form of therapy/treatment was used in the management of this case other than that described above.

The patient was instructed to return the following day for further evaluation. Upon her return, she reported that, following her treatment the day before, her coccygeal pain had gradually disappeared over the course of several hours, to the point at which only a feeling of residual "weakness" now remained in the area. Evaluation with the patient in a prone position revealed that the leg lengths appeared equal upon visual observation. No lumbopelvic involvement was detected at this time. However, examination with the coccygeal isolation testing procedure mentioned above continued to reveal the presence of coccygeal subluxation/facilitation, in spite of the patient's essentially asymptomatic status (ie, right leg length appeared to be one half inch shorter when patient tightened her buttocks muscles). The indicated coccygeal adjustment was given, as previously described, and again, re-isolation testing confirmed positive change wherein equal leg lengths were observed following said treatment. No further lumbopelvic adjustments were given to the patient over the course of her subsequent treatment.

The patient was seen 8 more times over a 3½-week period, with neuromechanical evidence of coccygeal involvement noted on each visit, although her subjective presentation continued to remain essentially asymptomatic each time. She returned to work after the third adjustment and was able to sit comfortably throughout the day. On the 11th visit, her asymptomatic status was accompanied by no objective findings of coccygeal subluxation/facilitation and no further feeling of weakness about the coccygeal area. She was dismissed from further care at that time, being asymptomatic with no objective findings of neuromechanical dysfunction. Follow-up at 3 months after treatment revealed that she had continued to remain free of coccygeal pain since termination of treatment.

DISCUSSION

This appears to be the first report of MFMA chiropractic treatment of coccygodynia with the AAI II and AMCT. Although only limited conclusions can be drawn from any single case study, this case did include a 3 week baseline before the initiation of treatment that helped to demonstrate the effectiveness of the subsequent therapeutic intervention (Fig 1). Although the baseline would be considered anecdotal in nature because no formal patient diary was kept prior to initiation of treatment, the patient's retrospective analysis of her level of pain prior to and following treatment does provide for a general overview of the response to therapy. In private clinical practice, it is not always possible to demonstrate a pretreatment baseline and many neuromusculoskeletal problems can be self-limiting. However, in this instance, correlating the 3-week baseline period of protracted coccygodynia with the patient's subsequent and essentially immediate response to the MFMA treatment by using AMCT would tend to strongly indicate that the improvement observed was a direct result of the treatment rendered. This conclusion is strengthened by the fact that no other form of treatment was used.

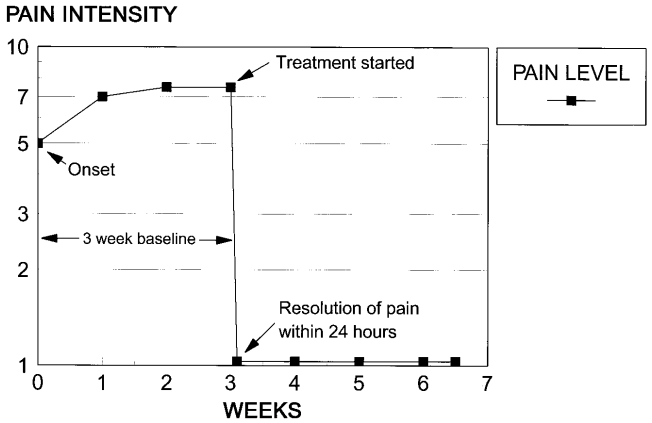

Fig 1. *Visual analog chart demonstrating the patient's 3 week pretreatment pain level and subsequent improvement with initiation of MFMA chiropractic treatment, using an AAI II.*

We have successfully treated similar cases over the years by using the above-described methodology. In the majority of cases, several adjustments are usually required to bring about an asymptomatic status (as opposed to the single one in this patient); however, this case serves to illustrate the benefit of MFMA chiropractic adjustment in certain cases of coccygodynia. Although there have been no large-scale studies regarding MFMA adjustments for coccygodynia, it has been our clinical experience, in over 20 years, that this methodology can provide effective relief for many such patients.

An interesting aspect worth noting is the fact that the radiologic, physical, and chiropractic examination findings corroborated each other; that is, all demonstrated the likelihood of a left lateral subluxation of the apex of the coccyx. Our clinical experience has been that this is not always the case. In those instances wherein the laterality of the coccygeal apex as viewed on radiographs differs from that detected upon physical examination, the findings derived from physical/chiropractic examination (by using the biomechanical diagnostic protocol of AMCT) should take precedence over those findings observed by radiography, if optimum therapeutic benefit is expected to occur from the subsequent adjustment.

There can be definitive benefits to utilizing this protocol for treatment of coccygodynia. Instrumental adjustment of the coccyx can provide for an easily administered, as well as comfortably tolerated, treatment for two primary reasons. First, the adjustment itself is a noninvasive procedure.

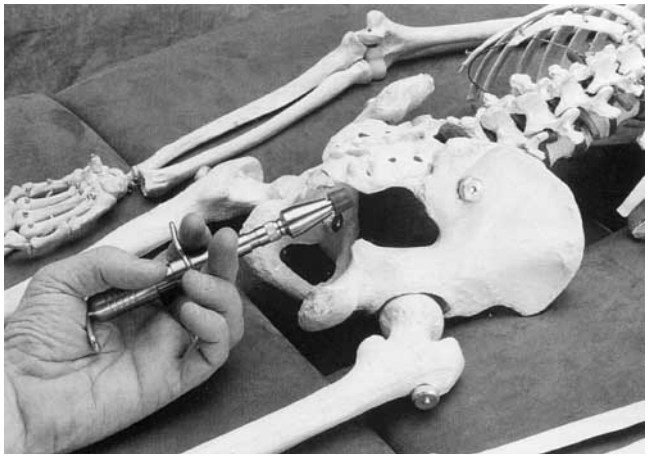

Fig 2. *Proper positioning of Activator Adjusting Instrument for correction of coccygeal subluxation. Contact is immediately lateral to the base of coccyx and line of drive is lateral and superior. Direct contact with the coccygeal apex is avoided. Correction of left lateral subluxation of the apex of the coccyx is depicted in photo. (Reproduced with permission from Fuhr AW, Colloca CJ, Green JR, Keller TS. Activator methods chiropractic technique. St. Louis, MO: Mosby; 1997:203.)*

Unlike per rectal manipulation, instrumental adjustment does not involve the uncomfortable and/or unpleasant task associated with that procedure. Patients can be understandably apprehensive of submitting to treatment via per rectal manipulation and tend to drop out of treatment early or avoid it altogether. Many chiropractic physicians do not perform intrarectal manipulation as part of their adjusting protocol. As a result, many patients presenting for chiropractic evaluation/treatment of coccygodynia have their treatment confined to manipulation of the lumbosacral spine in an effort to indirectly influence the coccygeal segments. Although this can be helpful in some cases, it stands to reason that, when indicated, specific adjustment directed toward influencing the coccyx directly would address the dysfunction more precisely, bringing with it a greater chance for quicker resolution of the problem.[12]

Also of importance is the fact that coccygeal manipulation per instrumental adjustment avoids any direct contact with the painful coccyx itself, as opposed to other manipulative methods.[12,13,15-17] Patients with coccygodynia often experience marked pain upon pressure to any aspect of the coccyx, particularly the tip.[12] This area is very tender to pressure, and making a segmental contact or adjustive thrust directly on the coccyx can cause the patient a great deal of discomfort, sometimes to the point of being intolerable. On the other hand, MFMA adjusting methodology, utilizing AMCT and an AAI II, involves contacting the area of the sacrococcygeal ligament rather than the apex of the coccyx itself.

To ensure an effective contact, we recommend that the clinician take a medial to lateral and inferior to superior tissue pull over the coccyx with the thumb of the free hand. The contact with the AAI is then made approximately one half inch lateral to the base of the coccyx on the side of soft tissue involvement (ie, side of "long" leg when the legs are flexed to 90 degrees) (Fig 2). It is important to note that this represents the side opposite the subluxation of the coccygeal apex. The line of drive of the adjustive thrust is vectored in a superior and lateral direction, with the thrust of the force being directed into the fibers of the sacrococcygeal ligament.[20] Although there may be some paracoccygeal soft tissue tenderness and even swelling present, this contact point, and the subsequent adjustive thrust delivered by the AAI, is usually comfortably tolerated even by a patient with the most acute coccygodynia. The AMCT coccygeal evaluation and adjusting protocol are summarized in Table 1; however, the clinician is well served by reviewing the complete protocol, as described in the AMCT textbook by Fuhr et al[20] for a more thorough understanding of the methodology involved.

Table 1. *Tests and adjustments for coccygeal subluxation utilizing activator methods chiropractic technique.*

Testing Procedure	Result	Procedure/Adjustment
Step One:		
Even leg lengths; instruct patient to squeeze buttocks together; observe leg lengths for change	PD leg shortens: indicates coccygeal subluxation.	Proceed to Step 2 in the testing procedure in order to determine laterality
	No change in leg lengths: coccygeal subluxation unlikely	Suspect referred pain of lumbosacral origin
Step 2:		
Flex legs to 90° and observe lengths	PD (short leg) becomes longer: apex subluxated contralaterally	Contact ½″ lateral to the *base* of the coccyx on the *same side* as PD. Line of drive is lateral and superior
	PD (short leg) becomes shorter: apex subluxated ipsilaterally	Contact ½″ lateral to the *base* of the coccyx on the *opposite side* as PD. Line of drive is lateral and superior

Proposed Mechanisms of Outcome

Although the precise neurophysiologic and biomechanical mechanisms involved in coccygodynia are poorly understood and in need of further investigation, the mechanical stimulus delivered by the AAI is thought to provide therapeutic benefit by the stimulation of the mechanoreceptive afferents located in the associated somatic tissues,[23,26,31] assisting in pain modulation through nociceptive inhibition.[37-39] AAI II adjustments may also serve to improve coccygeal kinematics through associated muscular changes following the intervention. The force produced by the AAI appears to be more than adequate to provide for mechanoreceptor stimulation, including even the type III high-threshold mechanoreceptors.[23,40,41]

The innervation of bovine coccygeal discs and longitudinal ligaments has demonstrated mechanoreceptors of morphology resembling Types 1-3 receptors.[42] There is increasing evidence of interaction between activity of mechanoreceptors and muscle activity in other joints and connective tissues.[43] Because they modulate muscle function, sensitized mechanoreceptors can excite muscle activity or even spasm at lower than normal levels of stimulation.[42] Consequently, adjust-

ments may indeed play a role in normalizing muscular tonicity and spasm associated with both pain and joint dysfunction.

Mechanoreceptor stimulation has been found to have an inhibitory effect on afferent pain pathways and efferent motoneuron activity.[37-39,44] Pain reduction following treatment with MFMA chiropractic adjustments may be due to coactivation of mechanically sensitive somatic afferents, whereas reduction of muscle spasm may result from concomitant inhibition of efferent motoneurons, as activation of joint mechanoreceptors is known to produce reflex inhibition of muscle function.[45,46] It has also been reported that the AAI may have a more direct effect on the soft tissue receptors or cutaneous nerve endings, as opposed to the various joint mechanoreceptors, and thereby indirectly influence joint dysfunction as well.[47,48] All of these mechanisms require further study and warrant formal investigation in a laboratory and, ideally, in an in vivo setting.

With regard to osseous kinematics, in the case of coccygeal manipulation, the adjustment need not affect a great deal of relative bone movement because, in coccygodynia, the associated pain is usually far greater than the degree of osseous displacement would indicate.[4] However, assuming that osseous movement is a necessary component of successful mechanical intervention, the AAI has been shown to be capable of producing relative bone movement in the thoracolumbar spine in vivo.[24,49] As such, the adjustive thrust imparted by the AAI may favorably influence the coccygeal disc structure and its respective mechanosensitive afferent nerve endings and fibers that have been reported to be intimately involved with the production of coccygodynia.[6]

Another possible mechanism of outcome in our case may have involved the chiropractic adjustment of the lumbosacral spine itself. Studies by Lora and Long[8] have shown that stimulation in and around the facet joints of L3-4, L4-5, and L5-S1 characteristically produce sensation or reproduce pain, unilaterally, in the coccygeal area. This phenomenon is particularly evident at the L5-S1 level. These findings led Cox to postulate that coccygodynia could, in fact, be another manifestation of lumbar degenerative disc disease.[7] In theory, this particular patient's coccygodynia relief might have been due as much to the reduction of mechanical pressure in the lumbosacral spine as to the direct adjustment of the coccygeal area itself. Indeed, the use of the AAI has been previously reported as effective in the treatment of selected lumbar disc disorders[27,50] and subluxations detected in the lumbosacral area were adjusted during the initial office visit, although not afterwards. As previously noted, however, although subsequent lumbosacral involvement was not detected after the first visit, examination for neurologic facilitation in the area of the coccyx remained positive for approximately 3 more weeks, accompanied by a feeling of persistent weakness in the area. As the patient's reflexes normalized with further treatment, the residual weakness resolved. These findings would suggest that coccygeal subluxation/facilitation was an important component of the patient's condition that needed to be addressed in order to affect a complete resolution of her problem.

CONCLUSION

Selected cases of coccygodynia can be effectively treated with manual manipulation when the causal factor is biomechanical in nature.[12,13] Based upon clinical observation, conservative chiropractic adjustment of the coccyx may be achieved through the use of mechanical force, manually assisted short-lever adjusting procedures, utilizing AMCT and an AAI in certain cases. This procedure may prove to provide for an effective delivery of the treatment in a manner that is both easy to administer and comfortably tolerated by the patient with coccygodynia. Consideration of this form of coccygeal manipulation should be made by those physicians who are called upon to treat this disorder. Further study should be made in an academic venue to classify and determine the most appropriate forms of treatment for different individuals with coccygodynia, treated in a chiropractic setting.

REFERENCES

1. Postacchini F, Massobrio M. Idiopathic coccygodynia: analysis of fifty-one cases and a radiographic study of the normal coccyx. J Bone Joint Surg 1983;65A:1116-24.
2. Maigne JY, Tamalet B. Standardized radiologic protocol for the study of common coccygodynia and characteristics of the lesions observed in the sitting position. Spine 1996;21:2588-93.
3. Wesselmann U, Reich SG. The dynias. Semin Neurol 1996; 16:63-74.
4. Schafer RC. Clinical biomechanics: musculoskeletal actions and reactions. Baltimore: Williams and Wilkins; 1983.
5. el-Khoury GY, Renfrew DL, Walker CW. Interventional musculoskeletal radiology. Curr Probl Diagn Radiol 1994;23:161-203.
6. Maigne JY, Guedj S, Straus C. Idiopathic coccygodynia—lateral roentgenograms in the sitting position and coccygeal discography. Spine 1994;19:930-4.
7. Cox JM. Low back pain: mechanism, diagnosis and treatment. 5th ed. Baltimore: Williams & Wilkins; 1997.
8. Lora J, Long D. So-called facet denervation in the management of intractable back pain. Spine 1976;1:121-6.
9. Handa T, Obata K, Tsugi H, Osada R, Ohshima H, Ishihara H. Effects of hydrostatic pressure on matrix synthesis and matrix metalloproteinase production in the human lumbar intervertebral disc. Spine 1997;22:1085-91.
10. Osada R, Tsuji H, Matsui H, Sakai K, Yudoh K, Ishihara H, Ohshima H. Autocrine/paracrine mechanism of insulin-like growth factor-1 secretion, and the effect of insulin-like growth factor-1 on proteoglycan synthesis in bovine intervertebral discs. J Orthop Res 1996;14:690-9.
11. Ohshima H, Bergel DH, Urban JP. Effect of static load on matrix synthesis rates in the intervertebral disc measured in vitro by a new perfusion technique. J Orthop Res 1995;13:22-9.
12. Wray CC, Easom S, Hoskinson J. Coccydynia. Aetiology and treatment. J Bone Joint Surg Br 1991;73:335-8.
13. Porter KM, Khan MAA, Piggot H. Coccydynia: a retrospective review. J Bone Joint Surg Br 1981;63-B:635-6.
14. Grosso NP, van Dam BE. Total coccygectomy for the relief of coccygodynia: a retrospective review. J Spinal Disord 1995; 8:328-30.
15. Robinson AG, Freedman LJ. Endometriosis and the anterior coccyx: observations on five cases. Res Forum 1985;1:120-2.
16. Mrozek JP. Coccygeal subluxation syndrome. In: Gatterman MI, editor. Foundations of chiropractic: subluxation. St Louis: Mosby–Year Book, Inc; 1995. p. 465-71.
17. Walters PJ. Pelvis. In: Plaugher G, Lopes MA, editors. Textbook of clinical chiropractic: a specific biomechanical approach. Baltimore: Williams & Wilkins; 1993. p. 150-89.

18. Fuhr AW, Osterbauer PJ. Strategies for the detection of neuromechanical dysfunction: activator methods isolation procedures and prone leg check. In: Proceedings of the Consortium for Chiropractic Research's 6th Annual Conference on Research and Education. Monterey, CA; June 21-23, 1991. Belmont: Consortium for Chiropractic Research; 1991:59-60.
19. Pettersson H, Arizzi P. Activator methods chiropractic technique work book, college edition. Phoenix, AZ: Activator Methods; 1988.
20. Fuhr AW, Colloca CJ, Green JR, Keller TS. Activator methods chiropractic technique. St. Louis, MO: Mosby; 1997.
21. Fuhr AW, Smith DB. Accuracy of piezoelectric accelerometers measuring displacement of a spinal adjusting instrument. J Manipulative Physiol Ther 1986;9:15-21.
22. Herzog W, Kawchuk GN, Conway PJ. Relationship between preload and peak forces during spinal manipulative treatments. Neuromusculoskeletal Sys 1993;1:52-8.
23. Osterbauer PJ, Fuhr AW, Hildebrandt RW. Mechanical force, manually assisted short lever chiropractic adjustment. J Manipulative Physiol Ther 1992;15:309-17.
24. Smith DB, Fuhr AW, Davis BP. Skin accelerometer displacement and relative bone movement of adjacent vertebrae in response to chiropractic percussion thrusts. J Manipulative Physiol Ther 1989;12:26-37.
25. Polkinghorn BS. Treatment of cervical disc protrusions via instrumental chiropractic adjustment. J Manipulative Physiol Ther 1997;21:114-21.
26. Osterbauer PJ, Fuhr AW, Keller TS. Description and analysis of activator methods chiropractic technique. In: Lawrence DJ, Cassidy JD, McGregor M, Meeker WC, Vernon HT, editors. Advances in chiropractic: volume 2. Chicago: Mosby; 1995. p. 471-520.
27. Richards GL, Thompson JS, Osterbauer PJ, Fuhr AW. Low force chiropractic care of two patients with sciatic neuropathy and lumbar disc protrusion. Am J Chiropractic Med 1990;3:25-32.
28. Dewitt JK, Osterbauer PJ, Stelmach G, Fuhr AW. Optoelectric measurement of leg length inequalities before, during and after isolation tests. In: Proceedings of the International Conference on Spinal Manipulation. Palm Springs, CA; June 10-11, 1994. Arlington: Foundation for Chiropractic Research and Education;1994:24-5.
29. Dewitt JK, Osterbauer PJ, Stelmach GE, Fuhr AW. Optoelectric measurement of changes in leg length inequality resulting from isolation tests. J Manipulative Physiol Ther 1994;17:530-8.
30. Youngquist MW, Fuhr AW, Osterbauer PJ. Interexaminer reliability of an isolation test for the identification of cervical subluxation. J Manipulative Physiol Ther 1989;12:93-7.
31. Osterbauer PJ, Fuhr AW. The current status of activator methods chiropractic technique, theory and training. Chiropr Technique 1990;2:169-75.
32. Haas M, Peterson D, Panzer D, Rothman EH, Soloman S, Krein R, Johansen R. Reactivity of leg alignment to articular pressure testing: evaluation of a diagnostic test using a randomized cross-over clinical trial approach. J Manipulative Physiol Ther 1993;16:220-7.
33. Haas M, Peterson D, Rothman EH, Krein R, Johansen R, Soloman S. Responsiveness of leg alignment associated with articular pressure testing to spinal manipulation: the use of a randomized clinical trial design to evaluate a diagnostic test with a dichotomous outcome. J Manipulative Physiol Ther 1993;16:306-11.
34. Slosberg M. Activator methods isolation tests. Todays Chiropr 1987;16:41-3.
35. Slosberg M. Activator methods: an update and review (part one). Todays Chiropr 1988;17:17-9.
36. Cooperstein R. Activator methods chiropractic technique. Chiropr Technique 1997;9:108-14.
37. Willis W, Coggeshall R. Sensory mechanisms of the spinal cord. 2nd edition. New York: Plenum Press; 1991.
38. Wyke BD. Articular neurology and manipulative therapy. In: Glasgow E, Twomey L, Scull E, Kleynhans A, Idczak R. editors. Aspects of manipulative therapy. 2nd edition. New York: Churchill-Livingstone; 1985. p. 72-7.
39. Gillette R. Potential antinociceptive effects of high level somatic stimulation—chiropractic manipulative therapy may coactivate both tonic and phasic analgesic systems. Some recent evidence. Trans Pac Consortium Res 1986;1:A4(1)-A4(9).
40. Brodeur R. The audible release associated with joint manipulation. J Manipulative Physiol Ther 1995;18:155-64.
41. Colloca CJ. Articular neurology, altered biomechanics, and subluxation pathology. In: Fuhr AW, Colloca CJ, Green JR, Keller TS. editors. Activator methods chiropractic technique. St. Louis: Mosby Year-Book, Inc; 1997. p. 19-64.
42. Roberts S, Eisenstein SM, Menage J, Evans EH, Ashton K. The innervation of bovine coccygeal discs and longitudinal ligaments has demonstrated mechanoreceptors of morphology resembling Types 1-3 receptors. Spine 1995;20:2645-51.
43. Shutte MJ, Happel LT. Joint innervation in joint injury. Clin Sports Med 1990;9:511-7.
44. Cox JM, Hazen LJ, Mungovan M. Distraction manipulation reduction of an L5-S1 disk herniation. J Manipulative Physiol Ther 1993;16:618-20.
45. Mclain RF. Mechanoreceptor endings in human cervical facet joints. Spine 1994;19:495-501.
46. de Andrade JR, Grant C, Dixon ASJ. Joint distention and reflex muscle inhibition in the knee. J Bone Joint Surg 1965;47-A:313-22.
47. Byfield D. Cervical spine: manipulative skill and performance considerations. Eur J Chiro 1991;39:45-52.
48. Haldeman S, Chapman-Smith D, Petersen D. editors. Modes of Care. In: Proceedings of the Mercy Center Conference: Guidelines for chiropractic quality assurance and practice parameters. Gaithersburg: Aspen; 1993. p. 108.
49. Nathan M, Keller TS. Measurement and analysis of the in vivo posteroanterior impulse response of the human thoracolumbar spine: a feasibility study. J Manipulative Physiol Ther 1994; 17:431-44.
50. Polkinghorn BS, Colloca CJ. Treatment of symptomatic lumbar disc herniation utilizing activator methods chiropractic technique. J Manipulative Physiol Ther 1998;21:187-96.